World Journal of Orthopedics

Submit a Manuscript: https://www.f6publishing.com

World J Orthop 2023 December 18; 14(12): 843-852

DOI: 10.5312/wjo.v14.i12.843

ISSN 2218-5836 (online)

ORIGINAL ARTICLE

Retrospective Study

Role of lateral soft tissues release in percutaneous hallux valgus correction: A medium term retrospective study

Fabio Zanchini, Ottorino Catani, Fabrizio Sergio, Alessia Boemio, Angelo Sieczak, Davide Piscopo, Salvatore Risitano, Gabriele Colò, Federico Fusini

Specialty type: Orthopedics

Provenance and peer review: Unsolicited article; Externally peer reviewed.

Peer-review model: Single blind

Peer-review report's scientific quality classification

Grade A (Excellent): 0
Grade B (Very good): 0
Grade C (Good): C
Grade D (Fair): 0
Grade E (Poor): 0

P-Reviewer: Nambi G, Saudi Arabia

Received: August 10, 2023
Peer-review started: August 10, 2023
First decision: September 28, 2023
Revised: October 12, 2023
Accepted: November 17, 2023
Article in press: November 17, 2023
Published online: December 18, 2023

Fabio Zanchini, Division of Orthopaedics and Traumatology, Multidisciplinary Department of Medical-Surgical and Dental Specialties, Clinical Orthopeadics, University of Campania "Luigi Vanvitelli", Naples 80138, Italy

Ottorino Catani, Department of Foot Surgery, Casa di cura Santa Maria, Santa Maria Capua Vetere 81055, Italy

Fabrizio Sergio, Department of Foot an Ankle Surgery, Casa di cura Santa Maria, Santa Maria Capua Vetere 81055, Italy

Alessia Boemio, Multidisciplinary Department of Medical-Surgical and Dental Specialties, Clinical Orthopeadics, AOU Luigi Vanvitelli, Napoli 80138, Italy

Angelo Sieczak, Davide Piscopo, Clinical Orthopeadics, University of Campania Luigi Vanvitelli, Naples 80138, Italy

Salvatore Risitano, Department of Orthopaedic and Traumatology, Orthopaedic and Trauma Centre, Città della Salute e della Scienza di Torino, Turin 10126, Italy

Gabriele Colò, Department of Orthopaedics and Traumatology, Regional Center for Joint Arthroplasty, ASO Alessandria, Alessandria 15121, Italy

Federico Fusini, Department of Orthopaedic and Traumatology, Regina Montis Regalis Hospital, Cuneo 12084, Italy

Corresponding author: Fabio Zanchini, MD, PhD, Professor, Division of Orthopaedics and Traumatology, Multidisciplinary Department of Medical-Surgical and Dental Specialties, Clinical Orthopeadics, University of Campania "Luigi Vanvitelli", Vico L. de Crecchio, Naples 80138, Italy. fabio.zanchini@unicampania.it

Abstract

BACKGROUND

In the field of minimally invasive surgery (MIS) for the treatment of hallux valgus (HV), different techniques have begun to emerge in the literature concerning the distal osteotomy of the first metatarsal bone, the synthesis or not of the metatarsal head, the possible association with lateral soft tissues release (LSTR) and osteotomy of the base of the first phalanx.

AIM
To evaluate the role of LSTR on percutaneous HV correction, evaluating functional and radiographical results.

METHODS
From January 2012 to May 2016 a total of 396 patients with mild to moderate symptomatic HV treated with the MIS technique were included in this retrospective study. The technique provides no internal fixation (WOS). Patients were divided into the LSTR group and no LSTR group (LSTR N). This surgical procedure (LSTR) was reserved for insufficient HV angle (HVA) correction during fluoroscopic control. Patients were evaluated at each follow-up by two other authors after appropriate training by senior authors (first practitioners). Clinical evaluation was performed before surgery, 6 mo after surgery, and 48 mo follow-up. American Orthopaedic Foot and Ankle Society (AOFAS) and visual analog scale (VAS) score was used to evaluate pain and function, and complications were recorded. In addition, the incidence of relapses and the degree of joint range of motion (ROM) with the association with the LSTR (capsule, adductor tendon, phalanx-sesamoid ligament, and the deep transverse metatarsal ligament) were evaluated. Radiological parameters included HVA and intermetatarsal angle (IMA). Patient satisfaction was assessed. Student *t*-test and Fisher exact test were used to assess statistical analysis.

RESULTS
From our study it is clear that no differences in term of HVA, VAS, IMA correction, rate of complications, and AOFAS score were found between groups, while a significant improvement of the same variables was found in each group between pre and postoperative values. A significant improvement in ROM at 6 mo (P = 0.018) and 48 mo (P = 0.02) of follow-up was found in LSTR N group. Complications were rare in both groups.

CONCLUSION
LSTR procedure on percutaneous HV correction seems to increase postoperative joint stiffness with a comparable incidence of relapse and a low incidence of complications.

Key Words: Hallux valgus; Percutaneous distal osteotomy; Lateral release; Minimally invasive surgery; Without ostheosynthesis; Range of motion

©The Author(s) 2023. Published by Baishideng Publishing Group Inc. All rights reserved.

Core Tip: Our study evaluated a court of 396 patients treated with percutaneous technique, pain particular attention to the influence of the lateral soft tissues release (LSTR) on postoperative joint range of motion (ROM) and hallux valgus recurrence. A significant difference in ROM was recorded in the group where the LSTR was carried out, while there was no superior incidence of relapse between groups. ROM was revealed better at follow-up in LSTR not performed group. We believe these data represent an essential element to understanding the etiopathogenesis of complications. This data also enhances the validity of minimally invasive surgery with no osteosynthesis technique.

Citation: Zanchini F, Catani O, Sergio F, Boemio A, Sieczak A, Piscopo D, Risitano S, Colò G, Fusini F. Role of lateral soft tissues release in percutaneous hallux valgus correction: A medium term retrospective study. *World J Orthop* 2023; 14(12): 843-852
URL: https://www.wjgnet.com/2218-5836/full/v14/i12/843.htm
DOI: https://dx.doi.org/10.5312/wjo.v14.i12.843

INTRODUCTION

Hallux valgus (HV) is a common and progressive deformity of the forefoot with a multifactorial etiology[1]. This pathology most frequently affects women between the ages of 40 and 60. This deformity occurs in younger patients when there is a pathology that causes an overload on the first ray[2]. HV is defined by a variable as angular deviation of the first ray greater than 15° with a progressive abduction and pronation of the first phalanx and adduction, pronation and elevation of the first metatarsal. In literature are described wide variety of bony procedures, including osteotomies at the level of the head, midshaft, and base of the first metatarsal, as well as arthrodesis of the first metatarsal-cuneiform joint. The surgical treatments can be associated or not with lateral soft tissues release (LSTR)[3-5]. HV's surgical management is made difficult not only by the complexity of pathology, but also by the absence of a surgical gold standard[6].

At present, minimally invasive surgery (MIS) is performed with minimal skin incisions (1-3 mm), under intraoperative X-ray guidance, and with or without internal fixation[7]. There is some confusion in the terminology used when referring to MIS or percutaneous surgery. The term percutaneous, which means made through the skin, should be utilized when there is no internal fixation (K-wire or screw), and MIS should be reserved for procedures with minimal incision but with osteosynthesis[8].

This percutaneous management combines different procedures according to the complexity of the deformity to be corrected[9-12]. These procedures have become popular among foot surgeons, most arising from the traditional open distal metatarsal osteotomy. The advantages of percutaneous procedure are: 1-d hospitalization, and decrease postoperative morbidity and shorter rehabilitation times, in addition patients better accept this technique[7,13].

The choice to perform the percutaneous technique for the correction of HV rather than open surgery is not commonly accepted among orthopedic surgeons, despite the fact that this technique has been widely used for several years and its equal efficacy, and sometimes its superiority, compared to the open technique has been widely demonstrated in the literature. The main debate is whether or not internal fixation should be used[14].

The alignment of the first ray by medial rotation of the first metatarsal head and distal metatarsal articular angle (DMAA) correction is obtained by Reverdin-Isham percutaneous osteotomy an intra-articular medial closing wedge osteotomy of the distal metatarsal, associated with an Akin osteotomy[15], both performed without osteosynthesis[10,13,16-18]. Reverdin-Isham is not a complete osteotomy, as the first metatarsal lateral cortex is preserved; the closing wedge ensures contact of the metatarsal head with the metaphysis. A special post-surgical corrective bandage makes internal fixation unnecessary. Due to early weight bearing, that technique allows the osteotomy to heal with the toe in its proper position[19].

MIS was introduced first in Spain and then in Europe by de Prado *et al*[18] and Lucas y Hernandez *et al*[20]. However, to our knowledge, no previous study has evaluated the long-term results of this technique. Thus, this prospective study aimed to evaluate the radiographic and clinical outcomes of patients with mild-to-severe HV treated by MIS with Reverdin-Isham and Akin percutaneous osteotomy following exostectomy and LSTR. The study aims to evaluate the role of LSTR on percutaneous HV correction, evaluating functional and radiographical results.

MATERIALS AND METHODS

Patients selection

From January 2012 to May 2016, 396 consecutive Caucasian patients with symptomatic HV from mild to moderate were enrolled in this study. All parties have been informed and have given their consent to the publication of the data. Of these patients, 79% (355) were women, and 10.35% (41) were men. The age ranged from 28 to 82 years (mean age 64 years). The surgical procedures were performed by two surgeons Fabio Zanchini, MD, PhD, Professor and Ottorino Catani, the supporters of MIS in southern Italy, who followed the patients in the outpatient evaluation and diagnosed the study participants. The surgical technique, the inclusion and exclusion criteria, the postoperative course, and the rehabilitation protocol were the same for both groups. Patients were evaluated at each follow-up by two other authors after appropriate training by senior authors (first practitioners). Standard follow-up was each week for the first 42 d, then at 3, 6, 9, and 12 mo, and then yearly for at least 4 years.

The inclusion criteria were: Patients with mild to moderate painful HV after at least 6 mo of conservative treatment without acceptable results. Mild to moderate bunions have been included. This criterion was defined by the evaluation of the value of the intermetatarsal angle (IMA), described as mild (IMA from 10° to 13°), moderate (IMA from 14° to 20°), and severe (IMA > 20°). Patients with concurrent deformities in the lesser toe and metatarsalgia that required an accessory surgical time of finger correction and Distal Minimally Invasive Metatarsal Osteotomy (DMMO) of the II-III-IV metatarsal were also included. The presence of a previous correction of HV on the contralateral side or bilateral deformities were not considered an exclusion criterion. Patients who underwent previous HV correction surgery on the same side, with hallux rigidus, flat foot with joint laxity, rheumatoid arthritis, or other inflammatory conditions were excluded. Patients with diabetes, peripheral neuropathy, psychiatric and infectious diseases were excluded.

All procedures were performed under regional anesthesia with a sciatic blockage at the level of popliteal fossa using a nerve stimulator to inject 10 mL of mepivacaine hydrochloride at 1.5%, with ultrasound guidance. Of the 396 patients enrolled in the study, all subjects received the same surgical treatment, postoperative protocol and rehabilitation. From them, 209 (53%) underwent additional LSTR, defined as the transverse section of the adductor hallucis and lateral hemicapsulotomy. This surgical procedure was reserved for insufficient HV angle (HVA) correction during fluoroscopic control. The other 187 patients (47%) did not require additional surgical time.

Radiographic evaluation

Radiographic examination in anteroposterior and lateral weight-bearing projection was performed in all patients in the preoperative, immediate postoperative, and during 6 wk, 3, 6, and 9 mo follow-up, and then yearly. Each time, the following parameters were evaluated: HVA (normal value < 15°) and IMA (normal value < 10°). In addition, bone callus formation and the vanishing of transparency lines were screened to exclude consolidation delay or pseudoarthrosis. The lack of consolidation was defined as the persistence of the transparency lines and lack of bone callus formation after 9 mo from surgery. HVA values in the last follow-up > 15° were considered HV relapse.

Clinical evaluation

All patients were clinically evaluated with the same protocol in the preoperative and subsequent follow-up stages. The American Orthopaedic Foot and Ankle Society (AOFAS) scale was performed preoperatively, at 6 mo, and the last follow-up (4 years) for a maximum of 100 points divided into the following categories: Toe alignment (max 15 points), functional ability (max 45 points), and pain (max 40 points). Particular emphasis was given to the range of motion (ROM) evaluation by analyzing the global extension and flection of the metatarsophalangeal joint (MTPJ) and considering > 100° of motion the normal value, as described by Shereff *et al*[21] with the ideal value of 110°. The ROM evaluation was

performed preoperatively, at 6 mo, and then at the last follow-up.

Statistical analysis

Continuous data were reported as mean and standard deviation, while categorical data were reported as rate. The statistical analysis was performed using the student *t*-test, using appropriate software Sigmaplot (Systat software Inc., San Jose, A, United States). Data of AOFAS, visual analog scale (VAS), and ROM were compared between groups where LSTR was performed (LSTR Y) and LSTR not performed (LSTR N) through a 2-tailed Student *t*-test. At the same time, the rate of non-union, metatarsalgia, and complications were evaluated between groups with Fisher exact test. The *P*-value was set at $P < 0.05$.

Surgical technique

All patients were treated with the same surgical technique, with percutaneous correction of HV (ICD-9-CM 727.1; ICD-10 M20.1), except for the group of LSTR, where latera release of soft tissue was performed. Both group wee trated with WOS technique (Figure 1). In this technique, the percutaneous osteotomy with a 2.0 mm × 12.0 mm Shannon burr (cat. 256018, FH Orthopedics SAS, Heimsbrunn, France) were performed extracapsulary in the subcapital region, perpendicular to longitudinal axis. The head can be translated up to 90% of first ray shaft diameter to recentering the sesamoids. In case of high DMAA with a curved proximal phalanx, Akin osteotomy was performed with 2.0 mm × 12.0 mm Shannon Burr. The lateral release, when performed, was obtained using a Beaver 64 scalpel (Rüttgers, Solingen, Germany). The incision is made on the most lateral part of the dorsal aspect of the MTPJ of the great toe, lateral to the extensor tendons and the scapel blade is inserted parallel to the extensor tendons. The blade is introduced deeply, entering the joint between the proximal phalangeal and metatarsal articular surfaces, until it is noted to be rubbing on the cartilage. The scapel blade is then advanced deeper until it reaches the inferolateral aspect of the base of proximal phalanx of the great toe, which is the point of insertion of the adductor tendon of the great toe. The blade is rotated 90° to orient the cutting edge laterally, and it is moved laterally. At the same time the great toe is moved medially, tensing the adductor to facilitate section of the tendon, which can be confirmed on fluoroscopy. Lateral metatarsophalangeal capsulotomy is then performed, preserving the dorsal half to avoid excessive destabilization of the joint[22].

Postoperative care

All patients followed the same postoperative protocol and were followed in the same way standardized by the two surgeons. There were no changes in postoperative protocol between groups. Weightbearing was allowed 3 h after surgery with a flat sole and rigid shoe. The bandage was maintained for 5 wk (Figure 2A), with replacement every 7-14 d. Upon removal of the bandage, patients were instructed to wear an interdigital silicone separator for two months as a night bracer. Upon removal of the bandage was prescribed the same rehabilitation protocol to all patients (10 sessions of assisted mobilizations of the I M-F, step rehabilitation, active exercises, *etc*.).

RESULTS

Forty-one male patients and 355 females were included in the study. Two-hundred-nine patients were included in the LSTR Y group, while 187 patients were included in the LSTR N group, with a mean age of 64 ± 16.02 years and 63.85 ± 16.85 years, respectively. Results of preoperative, 6 mo, and last follow-up values of HVA, IMA, ROM, AOFAS, and VAS were reported in Table 1, while the clinical feature is reported as the last case (Figure 2B). Group comparison showed no difference in the preoperative value of HVA ($P = 0.523$), IMA ($P = 0.686$), ROM ($P = 0.596$), AOFAS ($P = 0.882$), and VAS ($P = 0.924$).

A significant difference was found in ROM between groups at 6 mo ($P = 0.018423$) and the last follow-up ($P = 0.02$). No differences were found in terms of HVA at 6 mo ($P = 0.593197$), and last follow-up ($P = 0.929243$) and IMA at 6 mo ($P = 0.750608$) and last follow-up ($P = 0.649461$), AOFAS at 6 mo ($P = 0.841372$) and last follow-up ($P = 0.737018$) and VAS at 6 mo ($P = 0.263118$) and the last follow-up ($P = 0.413075$). The rate of non-union showed no significant differences between groups ($P = 0.4541$); the same was found for metatarsalgia ($P = 0.5502$).

Complications and management

No thromboembolic complications, no cases of hallux varus due to hypercorrection, and no cases of avascular necrosis were reported. No nerve injury was observed in any of the patients. Complications were observed in 37 patients (about 9%); 21 in the LSTR Y group and 16 in the LSTR N group. The reported complications showed no significant differences in the two groups ($P = 0.73$).

Four patients developed a superficial infection at the medial access to exostosis, all resolved by general and local antibiotic therapy for 4 wk. One patient developed a deep infection which was also resolved by specific antibiotic administration after isolation of the bacterium. Seven patients submitted a consolidation delay. They were treated with pulsed electromagnetic fields (2 applications per day for 30 d) and administration of clodronic acid. Four reached healing and the complete regression of the symptomatology (pain and swelling of the MTPJ) after 12 mo from surgery. Two patients developed asymptomatic pseudoarthrosis: 1 required reintervention due to pain persistence. After 6 mo, the consolidation was achieved, with regression of the symptoms but subsequent development of joint stiffness.

In 9 patients, the medial margin of the cortical created impingement with soft tissues; two patients refused reintervention, while in 7 patients, the problem was solved with percutaneous removal of the bone prominence. Eleven patients reported HV recurrence with a mild HVA value lower than the preoperative values; in 5 patients, exostosis relapsed.

Table 1 The main clinical and radiological features of patients included in the study preoperatively, at 6 mo, and at the last follow-up

	Preop		6 mo		Last follow-up	
	Soft tissue release	No soft tissue release	Soft tissue release	No soft tissue release	Soft tissue release	No soft tissue release
HVA	22.4 ± 5.26	22.74 ± 5.5	11.11 ± 2.01	11.22 ± 1.86	12.06 ± 1.39	12.07 ± 1.32
IMA	12.6 ± 1	12.61 ± 0.98	8.14 ± 1.36	8.18 ± 1.33	8.930 ± 1.35	8.99 ± 1.34
ROM	101.94 ± 9.64	102.46 ± 9.9	104.47 ± 7.9	106.28 ± 7.24	104.70 ± 6.07	105.96 ± 6.4
AOFAS	68.08 ± 8.51	67.95 ± 8.17	88.95 ± 8	88.79 ± 8	90.58 ± 6.3	90.37 ± 6.41
VAS	4.41 ± 1.12	4.42 ± 1.14	1.28 ± 1.01	1.39 ± 0.99	0.93 ± 0.76	0.99 ± 0.74

HVA: Hallux valgus angle; IMA: Intermetatarsal angle; ROM: Range of motion; AOFAS: American Orthopaedic Foot and Ankle Society; VAS: Visual analog scale.



DOI: 10.5312/wjo.v14.i12.843 **Copyright** ©The Author(s) 2023.

Figure 1 Preoperative clinical and radiological features of a 42 years female patient with hallux valgus. A: Preoperative clinical; B: Radiological features.

There was no significant prevalence between treatment groups (P = 0.7628). Four of these patients underwent re-intervention and then declared satisfied with the result. In 8 patients, medial exostosis relapsed. Insufficient debris removal and/or exostectomy were found in all these patients. Seven of them underwent a subsequent reintervention with percutaneous exostectomy. Nineteen patients reported severe stiffness at 6 mo follow-up, with no differences between groups (P = 0.4817). A significant improvement in joint stiffness was reached in 8 patients who performed intense physiotherapy. After the revision of the preoperative X-ray, mild signs of joint degeneration were already highlighted in 85% of patients with residual joint stiffness. Eleven patients reported transfer metatarsalgia: 7 to medium-term follow-up and 4 to long-term follow-up. Four of these patients were treated with plantar orthoses with no more pain. Seven patients requested a re-intervention of percutaneous dorsalization osteotomy (DMMO) of the II-III-IV metatarsal head with symptomatology resolution. Two of them subsequently developed metatarsalgia II-V which was treated with orthoses.

DISCUSSION

Studies concerning percutaneous or MIS for treating HV have increased exponentially in recent years[23-25]. Growing scientific evidence demonstrates the percutaneous MIS technique's effectiveness in treating mild to moderate bunions. Compared with open techniques, the results overlap with fewer complications and greater patient satisfaction[26,27].

Our study evaluated a court of 396 patients treated with WOS technique as described by Lucattelli *et al*[22], pain particular attention to the influence of the LSTR on postoperative joint ROM and HV recurrence. A significant difference in ROM was recorded in the group where the LSTR was carried out, while there was no superior incidence of relapse between groups. Moreover, it must be noted that the starting ROM influences the postoperative ROM after surgery.

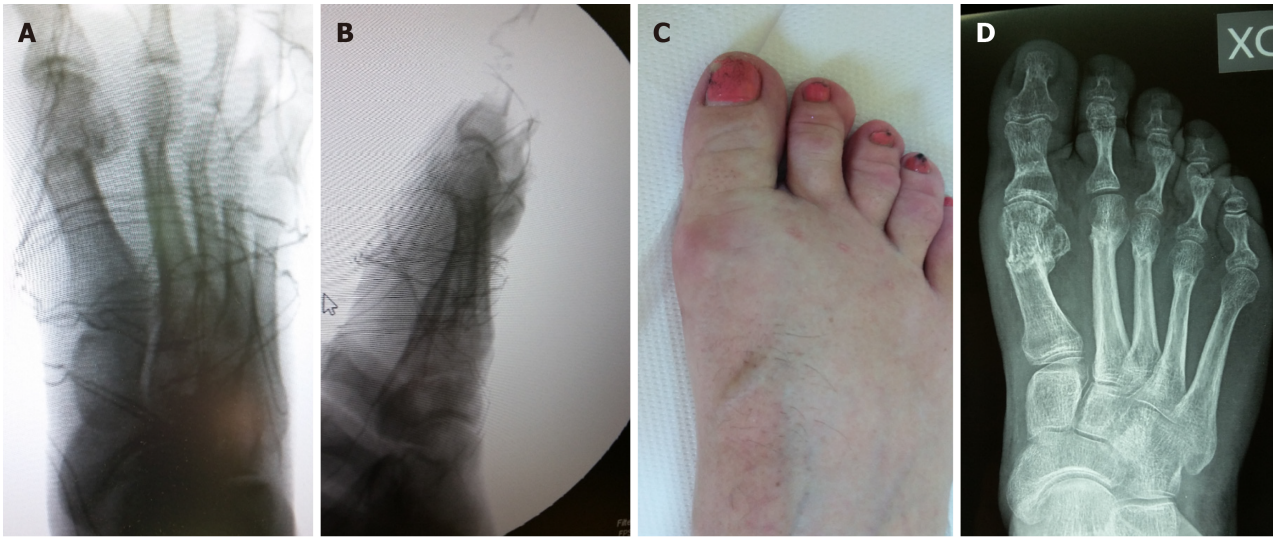

DOI: 10.5312/wjo.v14.i12.843 **Copyright** ©The Author(s) 2023.

Figure 2 Postoperative fluoroscopic picture of the patient treated with percutaneous hallux valgus correction without fixation (bandages) and follow-up. A: Postoperative fluoroscopic picture of the patient treated with percutaneous hallux valgus correction without fixation (bandages); B: Clinical and postoperative X-rays of the previous patients at 6 mo of follow-up.

According to the conclusions of the metanalysis of Izzo *et al*[28], we found no difference in AOFAS and recurrence rate between procedures, but ROM was revealed better at follow-up in LSTR N group, which was not directly investigated in the meta-analysis.

We believe these data represent an essential element to understanding the etiopathogenesis of complications. LSTR did not produce significant differences between the two groups regarding the increased incidence of relapses. This data also enhances the validity of MIS with no osteosynthesis technique. Being a step-by-step procedure, it allows us to reserve the LSTR as the last surgical gesture and carry it out exclusively when, from the intraoperative evaluation, sufficient metatarsal-phalangeal joint congruence has not been obtained[29].

The osteotomy practiced with a burr provided more significant shortening and joint decompression than the one performed with a blade[22,30]. We always associate Akin's osteotomy while keeping the medial cortical intact to balance the physiological loss of correction in post-op[31]. In agreement with Coughlin, the proper correction of DMMA allows the restoration of the balance of muscle forces at the level of the first ray in order to avoid adhesions and soft tissue retraction[1,32]. Our study reported better IMA correction than Reverdin and comparable results to Bauer *et al*[17] and Isham[19].

Our results demonstrated the reliability, durability, and lower incidence of complications of the technique than open techniques for HV correction[4,33]; we have recorded an incidence of complications of 9%, similar to other studies where the surgery was performed without fixation other than bandages[22,34-36] and fewer complications than studies with other MIS techniques[12,24].

According to Tournemine *et al*[37], we believe that the low incidence of this complication is due to our setting to practice DMMO in patients with particularly short metatarsals and patients with slightly and occasionally reported metatarsalgia[38,39]. Joint stiffness (global ROM < 95°) was recorded in 5.88% of patients treated without LSTR and 3.83% treated with LSTR, for a global rate of 4.8%. Some results could be justified by the lack of debris removal from the joint after exostectomy and partly by the lack of recognition of an initial hallux rigidus[40-42].

From the analysis of immediate postoperative radiography, we learned that the accurate removal of debris is a fundamental element, and two factors play a decisive role. The first is the image quality of the brightness amplifier during the intervention and the projection of the radiogram, which can be misinterpreted; and the second is the direct removal with the rasp towards the capsule to extract the fragments that often remain strictly attached to the capsule and are not easily removable even with saline solution irrigation[43]. To avoid the recurrence of exostoses we also recommend extending the exostectomy up to 2-3 mm beyond the profile of the medial cortex[25].

We reported a low percentage of pseudoarthrosis compared to those described in other different MIS techniques. In our view, it is one of the advantages of our technique. The removal of the exostosis makes it necessary for the axis correction with a lower head translation, which ensures more stability. Moreover, the osteotomy is performed intra-capsular and safely regarding bone consolidation[44,45]. The Bosch and SERI techniques needed a greater translation of the head, which is not modular. The infection rate is similar to other percutaneous studies, and it is lower than other studies analyzing treatment with K wire at a rate ranging from 0.8% to 8%[12,13,24,46].

As for most literature, no avascular necrosis was reported[47,48]. While even if rare, it was reported that an incidence of avascular necrosis ranges from 0.8% to 3.5%[49]. Low burr speed and continuous irrigation with saline solution are fundamental elements to avoid avascular necrosis and scrupulous respect for the osteotomy level[30]. We believe that the low incidence of transfer metatarsalgia is linked to our practice of DMMO (II-III-IV) in patients who report mild and occasional metatarsalgia, in particular in those in which a metatarsal formula with index minus is evidenced[30,50,51].

AOFAS score increased in both groups at 6 mo and last follow-up with increase in functional abilities and decrease in pain.

The study has several limitations; some are intrinsic to the study's retrospective nature, while others are intrinsic with the study design. The lack of randomization, priori sample size calculation, the lack of blindness, and the decision to perform soft tissue lateral release or not are the study's most critical limitations. The results of this study should be useful to surgeons treating these conditions. However, due to the lack of prospective studies in the literature regarding the LSTR procedure, we hope that our work will be a starting point for future prospective studies regarding this technique. We hope, in particular, that the aspect of joint stiffness will be deepened.

CONCLUSION

The percutaneous correction of HV is a reliable and safe procedure that significantly improves the AOFAS score and radiological angles, with a low risk of recurrence for the LSTR group. LSTR does not seem to affect pathology relapse, while the adequate correction of HVA remains the crucial factor. Early weight-bearing, minimal invasiveness, and the lack of internal fixation represent this technique's advantages. LSTR seems to increase postoperative joint stiffness with a comparable incidence of relapse and a low incidence of complications. This data also enhances the validity of MIS with no osteosynthesis technique. Being a step-by-step procedure, it allows us to reserve the LSTR as the last surgical gesture and carry it out exclusively when, from the intraoperative evaluation, sufficient metatarsal-phalangeal joint congruence has not been obtained.

ARTICLE HIGHLIGHTS

Research background

Several minimally invasive surgical techniques for the correction of hallux valgus (HV) have emerged in the literature. These techniques concern the distal osteotomy of the first metatarsal, the use or not of internal fixation, osteotomy of the base of the first phalanx (Akin osteotomy). All these techniques can be associated with the lateral release of soft tissues.

Research motivation

The lack of copious prospective studies regarding lateral soft tissues release (LSTR) procedure.

Research objectives

The object of this study is to evaluate the role of LSTR on percutaneous HV correction, evaluating functional and radiographical results.

Research methods

From January 2012 to May 2016, a total of 396 patients with mild to moderate symptomatic HV treated with the MIS technique were included in this retrospective study. The technique provides no internal fixation. Patients were divided into the LSTR group (LSTR Y) and no LSTR group (LSTR N). This surgical procedure (LSTR) was reserved for insufficient HV angle (HVA) correction during fluoroscopic control. Patients were evaluated at each follow-up by two other authors after appropriate training by senior authors (first practitioners).

Research results

We found a statistically significant difference in range of motion between the two groups (LSTR-N and LSTR-Y) at 6 mo ($P = 0.018423$) and the last follow-up ($P = 0.02$). There are no significant differences between groups for the other parameters assessed (HVA, intermetatarsal angle, American Orthopaedic Foot and Ankle Society, visual analog scale).

Research conclusions

LSTR does not seem to affect pathology relapse, while the adequate correction of HVA remains the crucial factor. LSTR seems to increase postoperative joint stiffness with a comparable incidence of relapse and a low incidence of complications.

Research perspectives

Because of the lack of copious prospective studies regarding LSTR procedure, we feel a more thorough literature review is presented with both prospective and retrospective analyses. The results of this study should be useful to surgeons treating this condition and can be used in the design of future investigations into the joint stiffness.

FOOTNOTES

Author contributions: Zanchini F, Catani O, and Sergio F designed the research study and performed the research; Boemio A, Sieczak A,

and Piscopo D analyzed the data and wrote the manuscript; Colò G and Fusini F share co-last authorship, and they revised the text of the manuscript; and all authors have read and approve the final manuscript.

Institutional review board statement: The study was reviewed and approved by the Comitato Etico dell'Istituto Clinica Ortopedica AOU Luigi Vanvitelli, Campania.

Informed consent statement: This is to certify that signature of a consent form for the study was waived by our Institutional Review Board for the current study because of its retrospective nature and part of our service evaluation assessment.

Conflict-of-interest statement: All the authors report no relevant conflicts of interest for this article.

Data sharing statement: Technical appendix, statistical code, and dataset available from the corresponding author at boemioale@gmail.com Participants gave informed consent for data sharing.

Open-Access: This article is an open-access article that was selected by an in-house editor and fully peer-reviewed by external reviewers. It is distributed in accordance with the Creative Commons Attribution NonCommercial (CC BY-NC 4.0) license, which permits others to distribute, remix, adapt, build upon this work non-commercially, and license their derivative works on different terms, provided the original work is properly cited and the use is non-commercial. See: https://creativecommons.org/Licenses/by-nc/4.0/

Country/Territory of origin: Italy

ORCID number: Fabio Zanchini 0000-0001-6438-3395; Alessia Boemio 0000-0002-8618-7640; Salvatore Risitano 0000-0003-4595-1531; Gabriele Colò 0000-0002-6838-6910; Federico Fusini 0000-0002-4223-8485.

S-Editor: Wang JJ
L-Editor: A
P-Editor: Xu ZH

REFERENCES

1 **Coughlin MJ**, Jones CP. Hallux valgus: demographics, etiology, and radiographic assessment. *Foot Ankle Int* 2007; **28**: 759-777 [PMID: 17666168 DOI: 10.3113/FAI.2007.0759]
2 **Castillo-López JM**, Munuera-Martínez PV, Algaba-Guisado C, Reina-Bueno M, Salti-Pozo N, Vargas-Macías A. Pathologic Disorders of the Foot in Professional Female Flamenco Dancers. *J Am Podiatr Med Assoc* 2016; **106**: 54-59 [PMID: 26895362 DOI: 10.7547/14-111]
3 **Stienstra JJ**, Lee JA, Nakadate DT. Large displacement distal chevron osteotomy for the correction of hallux valgus deformity. *J Foot Ankle Surg* 2002; **41**: 213-220 [PMID: 12194510 DOI: 10.1016/S1067-2516(02)80017-5]
4 **Baravarian B**, Briskin GB, Burns P. Lapidus bunionectomy: arthrodesis of the first metatarsocunieform joint. *Clin Podiatr Med Surg* 2004; **21**: 97-111, vi [PMID: 15012034 DOI: 10.1016/S0891-8422(03)00112-5]
5 **Biz C**, Corradin M, Petretta I, Aldegheri R. Endolog technique for correction of hallux valgus: a prospective study of 30 patients with 4-year follow-up. *J Orthop Surg Res* 2015; **10**: 102 [PMID: 26135394 DOI: 10.1186/s13018-015-0245-1]
6 **Trnka HJ**. Osteotomies for hallux valgus correction. *Foot Ankle Clin* 2005; **10**: 15-33 [PMID: 15831256 DOI: 10.1016/j.fcl.2004.10.002]
7 **Roukis TS**. Percutaneous and minimum incision metatarsal osteotomies: a systematic review. *J Foot Ankle Surg* 2009; **48**: 380-387 [PMID: 19423043 DOI: 10.1053/j.jfas.2009.01.007]
8 **Trnka HJ**. Percutaneous, MIS and open hallux valgus surgery. *EFORT Open Rev* 2021; **6**: 432-438 [PMID: 34267933 DOI: 10.1302/2058-5241.6.210029]
9 **Dennis NZ**, Das De S. Modified Mitchell's osteotomy for moderate to severe hallux valgus--an outcome study. *J Foot Ankle Surg* 2011; **50**: 50-54 [PMID: 21106414 DOI: 10.1053/j.jfas.2010.10.005]
10 **Magnan B**, Bortolazzi R, Samaila E, Pezzè L, Rossi N, Bartolozzi P. Percutaneous distal metatarsal osteotomy for correction of hallux valgus. Surgical technique. *J Bone Joint Surg Am* 2006; **88** Suppl 1 Pt 1: 135-148 [PMID: 16510807 DOI: 10.2106/JBJS.E.00897]
11 **Siclari A**, Decantis V. Arthroscopic lateral release and percutaneous distal osteotomy for hallux valgus: a preliminary report. *Foot Ankle Int* 2009; **30**: 675-679 [PMID: 19589315 DOI: 10.3113/FAI.2009.0675]
12 **Giannini S**, Faldini C, Nanni M, Di Martino A, Luciani D, Vannini F. A minimally invasive technique for surgical treatment of hallux valgus: simple, effective, rapid, inexpensive (SERI). *Int Orthop* 2013; **37**: 1805-1813 [PMID: 23820757 DOI: 10.1007/s00264-013-1980-8]
13 **Maffulli N**, Longo UG, Marinozzi A, Denaro V. Hallux valgus: effectiveness and safety of minimally invasive surgery. A systematic review. *Br Med Bull* 2011; **97**: 149-167 [PMID: 20710024 DOI: 10.1093/bmb/ldq027]
14 **Van Enoo RE**, Cane EM. Minimal incision surgery. A plastic technique or a cover-up? *Clin Podiatr Med Surg* 1986; **3**: 321-335 [PMID: 2938721]
15 **Redfern D**, Vernois J, Legré BP. Percutaneous Surgery of the Forefoot. *Clin Podiatr Med Surg* 2015; **32**: 291-332 [PMID: 26117570 DOI: 10.1016/j.cpm.2015.03.007]
16 **Laffenêtre O**, Millet-Barbé B, Darcel V, Lucas Y Hernandez J, Chauveaux D. Percutaneous bunionette correction: results of a 49-case retrospective study at a mean 34 months' follow-up. *Orthop Traumatol Surg Res* 2015; **101**: 179-184 [PMID: 25701161 DOI: 10.1016/j.otsr.2014.11.017]
17 **Bauer T**, de Lavigne C, Biau D, De Prado M, Isham S, Laffenétre O. Percutaneous hallux valgus surgery: a prospective multicenter study of 189 cases. *Orthop Clin North Am* 2009; **40**: 505-514, ix [PMID: 19773056 DOI: 10.1016/j.ocl.2009.05.002]
18 **de Prado M**, Ripoll PL, Vaquero J, Golanó P. Tratamiento quirúrgico percutáneo del hallux valgus mediante osteotomías múltiples. *Rev Esp Cir Ortop Traumatol* 2003; **47**: 406-416 [DOI: 10.1016/S1888-4415(03)76145-1]

19 **Isham SA**. The Reverdin-Isham procedure for the correction of hallux abducto valgus. A distal metatarsal osteotomy procedure. *Clin Podiatr Med Surg* 1991; **8**: 81-94 [PMID: 2015537 DOI: 10.1016/S0891-8422(23)00420-2]

20 **Lucas y Hernandez J**, Golanó P, Roshan-Zamir S, Darcel V, Chauveaux D, Laffenêtre O. Treatment of moderate hallux valgus by percutaneous, extra-articular reverse-L Chevron (PERC) osteotomy. *Bone Joint J* 2016; **98-B**: 365-373 [PMID: 26920962 DOI: 10.1302/0301-620X.98B3.35666]

21 **Shereff MJ**. Pathophysiology, anatomy, and biomechanics of hallux valgus. *Orthopedics* 1990; **13**: 939-945 [PMID: 2235742 DOI: 10.3928/0147-7447-19900901-06]

22 **Lucattelli G**, Catani O, Sergio F, Cipollaro L, Maffulli N. Preliminary Experience With a Minimally Invasive Technique for Hallux Valgus Correction With No Fixation. *Foot Ankle Int* 2020; **41**: 37-43 [PMID: 31437408 DOI: 10.1177/1071100719868725]

23 **Caravelli S**, Mosca M, Massimi S, Costa GG, Lo Presti M, Fuiano M, Grassi A, Zaffagnini S. Percutaneous treatment of hallux valgus: What's the evidence? A systematic review. *Musculoskelet Surg* 2018; **102**: 111-117 [PMID: 29081030 DOI: 10.1007/s12306-017-0512-x]

24 **Faldini C**, Nanni M, Traina F, Fabbri D, Borghi R, Giannini S. Surgical treatment of hallux valgus associated with flexible flatfoot during growing age. *Int Orthop* 2016; **40**: 737-743 [PMID: 26508497 DOI: 10.1007/s00264-015-3019-9]

25 **Catani O**, Fusini F, Zanchini F, Sergio F, Cautiero G, Villafañe JH, Langella F. Functional outcomes of percutaneous correction of hallux valgus in not symptomatic flatfoot: a case series study. *Acta Biomed* 2020; **91**: e2020065 [PMID: 32921761 DOI: 10.23750/abm.v91i3.8294]

26 **Pappas PG**, Kauffman CA, Andes DR, Clancy CJ, Marr KA, Ostrosky-Zeichner L, Reboli AC, Schuster MG, Vazquez JA, Walsh TJ, Zaoutis TE, Sobel JD. Clinical Practice Guideline for the Management of Candidiasis: 2016 Update by the Infectious Diseases Society of America. *Clin Infect Dis* 2016; **62**: e1-50 [PMID: 26679628 DOI: 10.1093/cid/civ933]

27 **Yassin M**, Bowirat A, Robinson D. Percutaneous surgery of the forefoot compared with open technique - Functional results, complications and patient satisfaction. *Foot Ankle Surg* 2020; **26**: 156-162 [PMID: 30737141 DOI: 10.1016/j.fas.2019.01.006]

28 **Izzo A**, Vallefuoco S, Basso MA, Ray R, Smeraglia F, Cozzolino A, Mariconda M, Bernasconi A. Role of lateral soft tissue release in percutaneous hallux valgus surgery: a systematic review and meta-analysis of the literature. *Arch Orthop Trauma Surg* 2023; **143**: 3997-4007 [PMID: 36352268 DOI: 10.1007/s00402-022-04693-x]

29 **Del Vecchio JJ**, Dalmau-Pastor M. Percutaneous Lateral Release in Hallux Valgus: Anatomic Basis and Indications. *Foot Ankle Clin* 2020; **25**: 373-383 [PMID: 32736735 DOI: 10.1016/j.fcl.2020.05.003]

30 **Fusini F**, Langella F, Catani O, Sergio F, Zanchini F. Mini-Invasive Treatment for Brachymetatarsia of the Fourth Ray in Females: Percutaneous Osteotomy With Mini-Burr and External Fixation-A Case Series. *J Foot Ankle Surg* 2017; **56**: 390-394 [PMID: 28089127 DOI: 10.1053/j.jfas.2016.10.015]

31 **Montiel V**, Yáñez Arauz JM, Suárez Á, Villas Tomé C, Alfonso Olmos-García M. Osteotomies of the second phalanx of the great toe: A clinical experience. *Foot (Edinb)* 2022; **53**: 101935 [PMID: 36037778 DOI: 10.1016/j.foot.2022.101935]

32 **Coughlin MJ**. Hallux valgus in men: effect of the distal metatarsal articular angle on hallux valgus correction. *Foot Ankle Int* 1997; **18**: 463-470 [PMID: 9278739 DOI: 10.1177/107110079701800802]

33 **Torrent J**, Baduell A, Vega J, Malagelada F, Luna R, Rabat E. Open vs Minimally Invasive Scarf Osteotomy for Hallux Valgus Correction: A Randomized Controlled Trial. *Foot Ankle Int* 2021; **42**: 982-993 [PMID: 34024185 DOI: 10.1177/10711007211003565]

34 **Baertich C**, Tablante AJC, Tablante EB, Lecoq M. Percutaneous, implantless basal closing wedge osteotomy for hallux valgus: Surgical technique and preliminary results in 114 patients. *Foot Ankle Surg* 2022; **28**: 1083-1088 [PMID: 35379571 DOI: 10.1016/j.fas.2022.03.005]

35 **Liszka H**, Gądek A. Percutaneous Transosseous Suture Fixation of the Akin Osteotomy and Minimally Invasive Chevron for Correction of Hallux Valgus. *Foot Ankle Int* 2020; **41**: 1079-1091 [PMID: 32659140 DOI: 10.1177/1071100720935036]

36 **Gutteck N**, Ulbricht M, Delank KS, Kielstein H, Schilde S. Minimally invasive hallux valgus correction with Internal Hallux Fixator® - A comparative cadaver study. *Foot Ankle Surg* 2022; **28**: 378-383 [PMID: 34275760 DOI: 10.1016/j.fas.2021.05.002]

37 **Tournemine S**, Calé F, Cazeau C, Bauer T, Stiglitz Y. Shortening effect influence of Distal Minimally Invasive Metatarsal Osteotomy in primary metatarsalgia. *Int Orthop* 2022; **46**: 983-988 [PMID: 34417638 DOI: 10.1007/s00264-021-05146-7]

38 **Samaila EM**, Ditta A, Negri S, Leigheb M, Colò G, Magnan B. Central metatarsal fractures: a review and current concepts. *Acta Biomed* 2020; **91**: 36-46 [PMID: 32555075 DOI: 10.23750/abm.v91i4-S.9724]

39 **Colò G**, Fusini F, Samaila EM, Rava A, Felli L, Alessio-Mazzola M, Magnan B. The efficacy of shoe modifications and foot orthoses in treating patients with hallux rigidus: a comprehensive review of literature. *Acta Biomed* 2020; **91**: e2020016 [PMID: 33559617 DOI: 10.23750/abm.v91i14-S.10969]

40 **Saur M**, Lucas Y Hernandes J, Barouk P, Bejarano-Pineda L, Maynou C, Laffenetre O. Average 4-Year Outcomes of Distal Oblique First Metatarsal Osteotomy for Stage 1 to 3 Hallux Rigidus. *Foot Ankle Int* 2022; **43**: 463-473 [PMID: 34747650 DOI: 10.1177/10711007211052298]

41 **Colò G**, Alessio-Mazzola M, Dagnino G, Felli L. Long-Term Results of Surgical Treatment of Valenti Procedures for Hallux Rigidus: A Minimum Ten-Year Follow-Up Retrospective Study. *J Foot Ankle Surg* 2019; **58**: 291-294 [PMID: 30850097 DOI: 10.1053/j.jfas.2018.08.055]

42 **Colò G**, Samaila EM, Magnan B, Felli L. Valenti resection arthroplasty for hallux rigidus: A systematic review. *Foot Ankle Surg* 2020; **26**: 838-844 [PMID: 31839478 DOI: 10.1016/j.fas.2019.11.009]

43 **Fusini F**, Alessandro M, Rava A, Kristijan Z, Felli L, Colò G. Aetiology, diagnosis, and treatment of brachymetatarsia: a narrative review. *Musculoskelet Surg* 2022; **106**: 99-109 [PMID: 34268706 DOI: 10.1007/s12306-021-00720-z]

44 **Martinelli N**, Cancilleri F, Marineo G, Marinozzi A, Longo UG, Denaro V. Pseudarthrosis after percutaneous distal osteotomy in hallux valgus surgery: a case report. *J Am Podiatr Med Assoc* 2012; **102**: 78-82 [PMID: 22232327 DOI: 10.7547/1020078]

45 **Ji L**, Wang K, Ding S, Sun C, Sun S, Zhang M. Minimally Invasive vs. Open Surgery for Hallux Valgus: A Meta-Analysis. *Front Surg* 2022; **9**: 843410 [PMID: 35388365 DOI: 10.3389/fsurg.2022.843410]

46 **Bösch P**, Wanke S, Legenstein R. Hallux valgus correction by the method of Bösch: a new technique with a seven-to-ten-year follow-up. *Foot Ankle Clin* 2000; **5**: 485-498, v [PMID: 11232393]

47 **Enan A**, Abo-Hegy M, Seif H. Early results of distal metatarsal osteotomy through minimally invasive approach for mild-to-moderate hallux valgus. *Acta Orthop Belg* 2010; **76**: 526-535 [PMID: 20973361]

48 **Magnan B**, Samaila E, Viola G, Bartolozzi P. Minimally invasive retrocapital osteotomy of the first metatarsal in hallux valgus deformity. *Oper Orthop Traumatol* 2008; **20**: 89-96 [PMID: 18338122 DOI: 10.1007/s00064-008-1231-0]

49 **Kadakia AR**, Smerek JP, Myerson MS. Radiographic results after percutaneous distal metatarsal osteotomy for correction of hallux valgus deformity. *Foot Ankle Int* 2007; **28**: 355-360 [PMID: 17371659 DOI: 10.3113/FAI.2007.0355]

50 **Arie EK**, Moreira NS, Freire GS, Dos Santos BS, Yi LC. Study of the metatarsal formula in patient with primary metatarsalgia. *Rev Bras Ortop* 2015; **50**: 438-444 [PMID: 26401502 DOI: 10.1016/j.rboe.2015.06.018]

51 **de Palma L**, Gigante A, Ventura A, Chillemi C. Regnauld procedure in the surgical treatment of metatarsalgia: interpretation of follow-up X-ray imaging. *J Foot Ankle Surg* 1997; **36**: 165-9; discussion 255 [PMID: 9232494 DOI: 10.1016/S1067-2516(97)80110-X]



Published by **Baishideng Publishing Group Inc**
7041 Koll Center Parkway, Suite 160, Pleasanton, CA 94566, USA
Telephone: +1-925-3991568
E-mail: bpgoffice@wjgnet.com
Help Desk: https://www.f6publishing.com/helpdesk
https://www.wjgnet.com



© 2023 Baishideng Publishing Group Inc. All rights reserved.