Acta Biomed 2020; Vol. 91, N. 3: e2020065 DOI: 10.23750/abm.v91i3.8294 © Mattioli 1885

Original article

Functional outcomes of percutaneous correction of hallux valgus in not symptomatic flatfoot: a case series study

Ottorino Catani[1], Federico Fusini[2], Fabio Zanchini[3], Fabrizio Sergio[1], Giovanni Cautiero[3], Jorge Hugo Villafane[4], Francesco Langella[5]

[1] Department of Foot an Ankle Surgery, Minerva Clinic, Santa Maria Capua a Vetere, Caserta, Italy; [2] Department of Orthopaedic and Traumatology, Regina Montis Regalis Hospital, ASL CN1, Mondovì, Italy; 3 Clinical Orthopaedics, University of Campania "Luigi Vanvitelli", Naples, Italy; [4] IRCCS Fondazione Don Carlo Gnocchi, Milan, Italy; [5] IRCCS Istituto Ortopedico Galeazzi, Milan, Italy

Summary. Hallux valgus (HV) and Pes Planus (PP) are two common conditions characterized by aesthetic dissatisfaction with or without pain. The aim of the study was to assess clinical and functional outcomes at two years follow-up of percutaneous surgery in patients with HV and concomitant not-symptomatic PP. From January 2014 to May 2015 a total of 12 females and 2 males (14 feet) were enrolled in the study (mean age 41.9±13.28). The inclusion criteria were patients with HV surgically treated with the percutaneous approach, mild or moderate not symptomatic PP at 24 months follow-up. Percutaneous distal metatarsal osteotomy and exostectomy is performed for all patients and followed by a weekly bandage. American Orthopaedic Foot and Ankle Society (AOFAS) score for HV (AOFAS-HV), patient satisfaction, and preoperative and postoperative X-ray at 6 weeks follow-up were evaluated. Numerical data are reported as the mean± SD and 95% confidence intervals. The pre-operative hallux valgus angle (HVA) was 30.14°±11.26°, the post-operative HVA was 18.36°±10.13 with a mean correction of 11.79°±2.67° with $p<0.0001$. Mean AOFAS-HV increased from 42.07±10.82 pre-operatively to 83±8.96 post-operatively with $p<0.0001$. One out of 14 patients had recurrence of HV without needing revision surgery at the last follow-up. All patients were satisfied with the clinical outcomes. Our results suggested that percutaneous osteotomy with the mini-burr is an effective treatment for patients with HV despite PP presence, even if the mean functional score was slightly worse when compared with the literature. (www.actabiomedica.it)

Key words: clinical outcome, functional outcome, minimally invasive, mini-burr, pes planus

Introduction

Hallux valgus (HV) and pes planus (PP) are two of most common reason to visit a foot and ankle surgeons for foot structural deformities. HV more commonly occurs in female than male (8:1) and is defined by a variable as angular deviation of the first ray greater than 15° with a progressive abduction and pronation of the first phalanx and adduction, pronation and elevation of the first metatarsal (1, 2).

A hallux valgus deformity is usually associated with abnormal foot mechanics, such as a contracted Achilles tendon, pes planus and generalized neuromuscular disease or inflammatory arthritic conditions, such as rheumatoid arthritis.

PP is more frequent in male patients and is defined by a collapse of the medial plantar arc with foot pointed outward. The aetiology and the correlation between these two clinical conditions still are debated and are thought to be multifactorial.

Hallux valgus correction requires careful consideration. The surgical approach for painful foot deformities is considered the gold standard. Up to date, a lot of surgical techniques were reported such as open

or percutaneous procedures. In particular, the percutaneous approach is progressively increasing its role and constant improvement are reported. The aim of the surgery is to correct the forefoot deformity and give a long-term functional and aesthetical satisfactory result (3).

In the case of simultaneous presence of PP, the therapeutic strategy is challenging, especially in not painful patterns. Treatment protocol for simultaneous surgical correction of both deformities is not described in the literature. Nevertheless, it is commonly performed when both deformities are severe and painful.

In our case series, we retrospectively evaluate fourteen patients treated using a percutaneous approach to correct HV with the simultaneous presence of mild and non-painful PP.

The aim of the study was to assess clinical and functional outcomes at two year follow-up of percutaneous surgery in patients with HV and concomitant not-symptomatic PP.

Patients and methods

From January 2014 to May 2015, 42 consecutive patients underwent percutaneous correction of symptomatic HV in our department. From them, we recruit 17 patients with concomitant PP, no distinction between acquired, secondary or congenital flat foot were applied. Sixteen patients underwent unilateral surgery while 1 had bilateral, due to symptoms and grade of HV. As an inclusion criterion, we consider PP all feet with a calcaneal inclination angle on weight-bearing lateral x-ray less than 20° (Figure 1). The mild and moderate grade of asymptomatic PPs were included in the study since severe PPs were all symptomatic and consequentially excluded. Four patients were lost at the minimum follow-up of 2 years and were then excluded. Finally, 12 females and 2 males (14 feet) were enrolled in the study. Mean age was 41.9±13.28. The demographic characteristics are listed in table 1. Before surgery, all patients were fully informed about the surgical procedure, post-operative care, and potential risk and complication of this procedure. All patients provided written informed consent and agree to surgical treatment proposed.

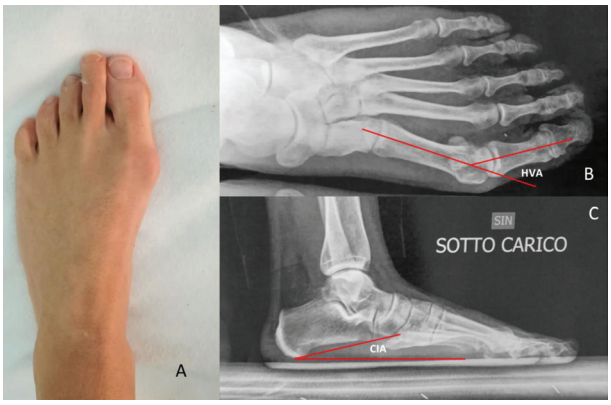

Figure 1. Pre-operative assessment of a 34-years old patient. **A** Pre-Operative Clinical photograph showing hallux valgus; **B** Pre-operative X-ray showing Hallux Valgus Angle (HVA) of 36°; **B** Pre-operative X-ray showing Calcaneal Inclination Angle (CIA) of 12°

Table 1. Demographic characteristic value

Participants (%)	14 (100)
Female gender (%)	12 (85.7)
Age (yr)	
Mean±SD	41.92±13.28
Comorbidity	
None (%)	14 (100)
Laterality	
Left main symptomatic (%)	6 (42.9)
Right main symptomatic (%)	8 (57.1)

Alignment of the first ray was assessed through hallux valgus angle (HVA) (4), defined as the angle between the longitudinal axis of first metatarsal and the longitudinal axis of proximal phalanx. A value greater than 15° was considered pathognomonic of hallux valgus. No distinction between HV degrees were established as an inclusion criterion. American Orthopaedic Foot and Ankle Society (AOFAS) score for HV (AOFAS-HV) (5) was used to assess clinical function before and after treatment. AOFAS-HV is an 8 entry questionnaire with a maximum total score of 100. The score was divided into three main section: pain (40 points), function (45) and alignment (15). Patients satisfaction for surgical treatment was also recorded at final follow-up.

Surgical technique

All procedures were performed by the same surgeon (O.C.). The patient is positioned in supine position, under ankle block anaesthesia and without tourniquet. A 2-mm skin incision was performed at the level of the first metatarsal head, just marginal to bunion. Bursal removal was obtained with straight burr 2.15 and cylindrical burr 3.15 and to avoid bone necrosis we used burr speed 2000-6000 rpm and tissues were irrigated with physiological solution. From the same access. we performed the distal metatarsal osteotomy with mini-burr (Shannon 44, Miltex Instrument, Co., Inc., Rietheim-Weilheim, Germany).

The osteotomy line was perpendicular to the first metatarsal longitudinal axis with inclination of 30° on the sagittal plane. To achieve the best and stable reduction, the tenotomy of the transverse head of adductor halluces can be performed, with or without osteotomy of the basis of proximal phalanx head.

To stabilize osteotomy, we preferred to use weekly bandage that allowed us to stabilize and modulate hallux correction during time as introduced by Bauer et al. (6).

Post-operative care

Full weight-bearing was allowed immediately the first postoperative day with an orthopaedic shoe (Podalux, DJO Global, Surrey, United Kingdom). Cane or other supports were not necessary for walking; However, some patients preferred to use them in the first weeks after surgery.

Radiographic evaluations were performed every 2 weeks while the renewal of bandages was performed weekly (Figure 2). Clinical examination and bandages were performed for 5 consecutive weeks and a new radiological examination was performed at 2 and 5 weeks along with bandages removal and then at 6 months and yearly. Patients continued to wear the orthopaedic shoe for a total of 5 weeks and comfortable shoes for other 4 weeks. A nocturnal retractor was positioned for the first month after bandage removal.

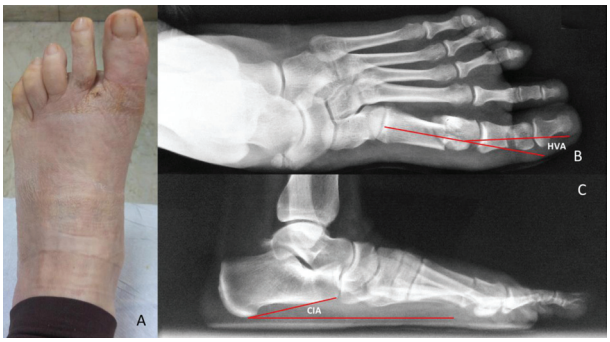

Figure 2. Post-operative assessment of a 40-years old patient. **A** Post-Operative Clinical photograph showing hallux valgus correction after bandage removal; **B** Pre-operative X-ray showing Hallux Valgus Angle(HVA) of 12°; **B** Pre-operative X-ray showing Calcaneal Inclination Angle (CIA) of 11°

Statistical analysis

Mean±standard deviation and 95% Confidence interval was calculated for AOFAS-HV and HVA. AOFAS-HV was also divided into three main section. Mann-Whitney U test was used to evaluate changes in HVA and AOFAS-HV values. Level of significance was set at $p<0.05$.

Assessors

One of us (F.F.) performed the radiographic measurements, data collection, statistical analysis, and language editing. Two of us (O.C., J.H.V. and F.Z.) performed study design, manuscript and image preparation; all procedures were carried out by the same surgeon (O.C.). Three others (F.L., G.C., FS) recruited the patients and collected pre-operative and post-operative outcome assessment. All Authors reviewed and approved the final manuscript.

Results

Before treatment mean HVA was 30.14°±11.26° while after the surgical procedure the mean correction was 18.36°±10.13 and a mean value of 11.79°±2.67° with p<.0001. Mean AOFAS-HV increased from 42.07±10.82 preoperatively to 83±8.96 postoperatively with p<.0001 (Table 2). Mean AOFAS-HV in-

Table 2. Clinical outcomes

Variable	**AOFAS - HV**
Pre-Operative	
Mean±SD	42.07±10.82
95% CI	35.83 to 48.32
Post-Operative	
Mean±SD	83±8.96
95% CI	77.83 to 88.17
p Value	<0.00001

Abbreviations: AOFAS - HV, American Orthopaedic Foot and Ankle Society Hallux Valgus Score; CI, confidence interval; SD, standard deviation

Table 3. Radiographic outcomes

Variable	**HVA** (°)
Pre-Operative	
Mean±SD	30.14±11.26
95% CI	23.64 to 36.64
Post-Operative	
Mean±SD	11.79±2.67
95% CI	10.25 to 13.32
p Value	< 0.00001

Abbreviations: HVA, Hallux Valgus Angle; CI, confidence interval; SD, standard deviation

creased from 42.07±10.82 pre-operatively to 83±8.96 post-operatively with p<.0001 (Table 3). Mean AOFAS HV pain subsection increased from 20.71±9.97 to 32.14±6.99 with p=.00386. Mean AOFAS HV function subsection increased from 21.36±6.42 to 36.86±4.22 with p<.0001. Mean AOFAS HV alignment subsection increased from 0±0 to 14±2.54 with p<.0001.

One out of 14 patients had recurrence of HV with an HVA of 18° at 6 months, stable at last follow-up at 24 months without needing revision surgery. Another patient had an HVA considered at the upper limits of the norm after surgical correction.

All patients were satisfied with the surgical procedure and will undergo the same procedure on the contralateral side in future, if necessary.

Discussion

In our study, we analyzed the functional outcome of patients undergoing percutaneous hallux valgus correction when concomitant non-painful PP is present. This surgical procedure demonstrates to be an effective and safe approach for HVA whit satisfactory results for all patients.

Both deformities represent the main reasons for consulting a foot surgeon. On one side, HVA is the most common foot deformity affecting the 23% of adults and 35.7% of elderly individuals (7). On the other hand, PP represents the 20% of adult people with 50 % of all these cases defined as asymptomatic depression of the longitudinal arch (8) otherwise require surgical approach (9, 10).

Despite the large distribution in the population, the association between HVA and PP is still debated in the scientific community.

Kilmartin and Wallace founded that the incidence of PP in HV patients and in the healthy population is essentially the same as well as the post-operative outcome when HV surgical correction is performed. In particular, this study underlined that the height of the plantar arch did not affect the clinical outcome of HV correction and its natural history (11).

Likewise Canale et al. (12) have reported no correlation between PP and the success rate of surgical repair of HVA deformity correction.

One limitation of these studies is related the confounding factor that several radiographic parameters are developed to describe the amount of PP. Giving that, the calcaneal inclination angle, navicular height, clinical observations and arch index, pes planus foot type represent the most commonly used instrument to classify the PP. According to these multiple options of measurement of PP, it is reasonable to found studies with an opposite opinion regarding the correlation between these foot deformities.

According to our knowledge, this is the first study aimed to investigate the surgical and clinical outcomes in patients affected by HV and treated with percutaneous approach when concomitant PP is present.

Several authors have suggested that HV deformity tends to develop in a pronated foot related with PP. In rheumatoid arthritis, the correlation between

these two deformities seems higher when compared to the normal population and for these reasons several authors have proposed to study in the horizontal and sagittal planes systematically. The aim is to reveal any basal phalanx displacement and not to miss the coexistence of flatfoot deformity (13).

Coughlin et al. (14) have suggested that several of structural factors may be characteristic of HV, including PP and even the development is multifactorial and the exact aetiology remains unexplained. Also not representing the primary cause, the concomitant presence of both the deformities may increase the risk of a rapid HV progression (15).

From a biomechanical point of view, the presence of adult-type pes planus causes pronation of the foot and hind-foot valgus. The first ray rotation is the natural consequence of foot pronation; the result is that the axis of the MTP joint is in an oblique plane relative to the floor. This excessive lateral pressure on the distal part of the proximal phalanx may induce HAV deformity.

The intimate relationship between the deformities encouraged Matsumoto et al. (16) to propose a classification based on 5 patterns of presentation according to the characteristic of HV and PP.

Giving that, several authors proposed to potentially increase the clinical outcomes with a simultaneous correction of both the deformities. Nevertheless, the treatment protocol of simultaneous correction are not described in the literature, this approach is mainly performed in the juvenile HV and represents a valuable option in the painful flatfoot (17).

The decision-making process in hallux valgus surgery passes through the awareness that not all hallux valgus deformities are equal and the revision rate is high (18).

The main limitation of the previous studies is that no one proposed a real therapeutic strategy to approach both the deformities. In our study, the surgical procedure focused on the correction of HV and no surgical solution was taken into consideration for the PP for its mild degree and not painful.

Percutaneous and minimally invasive surgery is considered as one of the most significant advances in the treatment of foot deformities. The percutaneous HV surgery is aimed to potentially decreased recovery and reduce rehabilitation and operative times with minimal soft tissue damage and low level of pain in the postoperative period (19).

In our study, the osteotomies were stable without internal fixation and the correction intraoperatively reached was maintained with a crepe bandage. Moreover, the renewal of dressings each week allowed the surgeon to modulate HV correction over time.

Thanks to their ability to reach regional deformity with minimal soft tissue damage these procedures are associated with less blood loss, short postoperative recovery and less injury to the soft tissue. Through recent acquisitions, percutaneous procedure brings powerful correction tools directly to the heart of the problem.

Several studies underline that the experience in percutaneous surgery and postoperative management are probably the main factors for the improvement of long-term results (6).

The scientific community does not equally consider the percutaneous procedures.

According to Kadakia (20) and colleagues, these procedure does not allow to reach an adequate correction of the DMAA (distal metatarsal articular angle), with a higher risk of overcorrection, recurrence and worst clinical results when compared with conventional open surgery. In particular, they report a high rate of early complication, non-union, and recurrence of HVA.

In our series one out of 14 patients had a recurrence of HV with an HVA of 18° at 6 months, the loss of correction was stable at last follow-up at 24 months. Nevertheless, the patient was satisfied of aesthetical and functional results, any revision surgery was required.

In numerous studies (19, 21), the percutaneous procedures ware defined at least as effective as traditional approaches for functional results and patient satisfaction.

Our results have shown to be comparable with results of previous studies in terms of surgical correction and clinical outcomes. However, the small sample size and some bias must be related to a low number of cases and a non-homogeneous population stratification by foot deformity.

According to a recent systematic review (19), the average correction of the HVA improved from a

pre-operative value of 29.6° (range 24.8° to 34.2°) for cases of mild to moderate HV to 13.2° (range 7.3° to 15.5°) post-operatively. In cases of moderate to severe HV, the preoperative and postoperative HVA was 41.5° (range 40.2° to 43°) and 13.2° (10.51° to 16°), respectively, using double percutaneous osteotomy. This study finally underlined the powerful capabilities of percutaneous approach.

Comparing our radiographic results after hallux valgus surgical correction between studies may be difficult because of subject selection and variability of severity of preoperative deformity, nevertheless, our results seem comparable to other studies.

From a functional point of view, the average postoperative AOFAS ranged from 84 (22) performing percutaneous double osteotomy surgical technique (Percutaneous Chevron Osteotomy) to 96.62 (23) performing a Reverdin-Isham procedure.

Even the encouraging result up to now it is not possible to determine precise recommendations regarding the systematic use of minimally invasive surgery for hallux valgus correction (21), and the therapeutic strategy is furthermore challenged by the simultaneous presence of PP. A physician should be aware of possible progression of deformity, for this reason, the use of prefabricated or custom orthoses or surgically approach this secondary deformity may be beneficial.

Our results suggested that the percutaneous approach represents an effective treatment for HV correction in patients with PP. The lack of the main complications, clinically relevant recurrence at 24 months follow-up, and the presence of good functional outcomes make it a valuable treatment choice (24).

When compared with the data presented in the literature, our series of patients shows slightly worst clinical outcome in term of AOFAS results at 24 months.

Some limitations are related to the small number of patients, the lack of a control group and randomization. Also, an a priori sample size calculation was not done. We were also limited by the lack of published data on the percutaneous approach of HV in PP deformity to compare with.

In our opinion, PP may be considered as an independent predictor of clinical outcomes and risk factor modifiable through intervention (e.g., footwear fit and heel height). This study has highlighted that this factor warrants further investigation using rigorous study methodology and further assessment is necessary to confirm the good clinical results and the absence of loss of correction over time.

Conclusion

The study aimed to analyze the functional outcome of patients undergoing percutaneous surgical procedure for hallux valgus correction in patients with pes planus. Even if results were graded as good, the study showed that the mean functional score was slightly worse when compared with the scores presented in the literature for percutaneous surgery.

In conclusion, we should carefully examine the feet of patients who will undergo reconstructive surgery for HV deformity because of the contextual presence of PP, though not painful, seems to play a role in the functional result, if not adequately treated. Further studies should be aimed to identify the PP as an independent predictor of post-operative functional outcome.

Patient consent: All patients gave informed consent prior to inclusion in the study.

Ethical approval: All procedures involving human participants were in accordance with the 1964 Helsinki Declaration and its later amendments. The study was approved by the Research Ethics Committee.

Conflict of interest: Each author declares that he or she has no commercial associations (e.g. consultancies, stock ownership, equity interest, patent/licensing arrangement etc.) that might pose a conflict of interest in connection with the submitted article

References

1. Crevoisier X, Assal M, Stanekova K. Hallux valgus, ankle osteoarthrosis and adult acquired flatfoot deformity: a review of three common foot and ankle pathologies and their treatments. EFORT Open Rev. 2016;1(3):58-64. doi:10.1302/2058-5241.1.000015
2. Usuelli F, Palmucci M, Montrasio UA, Malerba F. Radiographic Considerations of Hallux Valgus versus Hallux Rigidus. Foot Ankle Int. 2011;32(8):782-788. doi:10.3113/FAI.2011.0782

3. Yassin M, Bowirat# A, Robinson D. Percutaneous surgery of the forefoot compared with open technique — Functional results, complications and patient satisfaction. Foot Ankle Surg. January 2019. doi:10.1016/j.fas.2019.01.006
4. Deenik AR, de Visser E, Louwerens JW, de Waal Malefijt M, Draijer FF, de Bie RA. Hallux valgus angle as main predictor for correction of hallux valgus. BMC Musculoskelet Disord. 2008;9:70. doi:10.1186/1471-2474-9-70
5. Kakwani R, Siddique M. Clinical rating systems for the ankle-hindfoot, midfoot, hallux, and lesser toes. In: Classic Papers in Orthopaedics. ; 2014:217-219. doi:10.1007/978-1-4471-5451-8_53
6. Bauer T, de Lavigne C, Biau D, De Prado M, Isham S, Laffenétre O. Percutaneous Hallux Valgus Surgery: A Prospective Multicenter Study of 189 Cases. Orthop Clin North Am. 2009;40(4):505-514. doi:10.1016/j.ocl.2009.05.002
7. Nix S, Smith M, Vicenzino B. Prevalence of hallux valgus in the general population: a systematic review and meta-analysis. J Foot Ankle Res. 2010;3(1):21. doi:10.1186/1757-1146-3-21
8. Coughlin MJ, Saltzman CL, Anderson RB. Mann's Surgery of the Foot and Ankle.; 2014. doi:10.1016/B978-0-323-07242-7.00051-6
9. Usuelli FG, Di Silvestri CA, D'Ambrosi R, Maccario C, Tan EW. Return to sport activities after medial displacement calcaneal osteotomy and flexor digitorum longus transfer. Knee Surg Sports Traumatol Arthrosc. October 2016:1-5. doi:10.1007/s00167-016-4360-2
10. Usuelli FG, Montrasio UA. The Calcaneo-Stop Procedure. Foot Ankle Clin. 2012;17(2):183-194. doi:10.1016/j.fcl.2012.03.001
11. Kilmartin TE, Wallace WA. The significance of pes planus in juvenile hallux valgus. Foot Ankle. 1992;13(2):53-56. doi:10.1097/01241398-199207000-00047
12. Canale PB, Aronsson DD, Lamont RL, Manoli 2nd A. The Mitchell procedure for the treatment of adolescent hallux valgus. A long-term study. J Bone Jt Surg Am. 1993;75(11):1610-1618.
13. Matsumoto T, Nakada I, Juji T, Nakamura I, Ito K. Radiologic Patterning of Hallux Deformity in Rheumatoid Arthritis and Its Relationship to Flatfoot. J Foot Ankle Surg. 2016;55(5):948-954. doi:10.1053/j.jfas.2016.04.011
14. Coughlin MJ, Jones CP. Hallux Valgus: Demographics, Etiology, and Radiographic Assessment. Foot Ankle Int. 2007;28(7):759-777. doi:10.3113/FAI.2007.0759
15. Nix SE, Vicenzino BT, Collins NJ, Smith MD. Characteristics of foot structure and footwear associated with hallux valgus: A systematic review. Osteoarthr Cartil. 2012;20(10):1059-1074. doi:10.1016/j.joca.2012.06.007
16. Choi JY, Yoon HH, Suh YM, Suh JS. Surgical correction of hallux valgus complicated with adult-type pes planovalgus. J Orthop Surg. 2017;25(1):230949901668432. doi:10.1177/2309499016684320
17. Faldini C, Nanni M, Traina F, Fabbri D, Borghi R, Giannini S. Surgical treatment of hallux valgus associated with flexible flatfoot during growing age. Int Orthop. 2016;40(4):737-743. doi:10.1007/s00264-015-3019-9
18. Usuelli FG, Tamini J, Maccario C, Grassi M, Tan EW. Bone-block arthrodesis procedure in failures of first metatarsophalangeal joint replacement. Foot Ankle Surg. 2017;23(3):163-167. doi:10.1016/j.fas.2017.03.003
19. Bia A, Guerra-Pinto F, Pereira BS, Corte-Real N, Oliva XM. Percutaneous Osteotomies in Hallux Valgus: A Systematic Review. J Foot Ankle Surg. 2017:1-8. doi:10.1053/j.jfas.2017.06.027
20. Kadakia AR, Smerek JP, Myerson MS. Radiographic Results After Percutaneous Distal Metatarsal Osteotomy for Correction of Hallux Valgus Deformity. Foot Ankle Int. 2007;28(3):355-360. doi:10.3113/FAI.2007.0355
21. Maffulli N, Longo UG, Marinozzi A, Denaro V. Hallux valgus: Effectiveness and safety of minimally invasive surgery. A systematic review. Br Med Bull. 2011;97(1):149-167. doi:10.1093/bmb/ldq027
22. De Lavigne C, Rasmont Q, Hoang B. Percutaneous double metatarsal osteotomy for correction of severe hallux valgus deformity. Acta Orthop Belg. 2011;77(4):516-521.
23. Barragán-Hervella RG, Morales-Flores F, Arratia-Ríos M, Buzo-Garcidueñas AY, Nesme-Avila W, García-Villaseñor A. [Clinical results of hallux valgus minimally surgery]. Acta Ortop Mex. 2008;22(3):150-156.
24. Lucattelli G, Catani O, Sergio F, Cipollaro L, Maffulli N. Preliminary Experience With a Minimally Invasive Technique for Hallux Valgus Correction With No Fixation. Foot Ankle Int. 2020 Jan;41(1):37-43. doi: 10.1177/1071100719868725. Epub 20111,5

Received: 13 March 2019
Accepted: 20 January 2020
Correspondence:
Federico Fusini M.D.
Department of Orthopaedic and Traumatology,
Orthopaedic and Traumatologic Center, University of Turin,
Via G. Zuretti 29, Turin, Italy
Tel. +393208237090
E-mail: fusinif@hotmail.com