Clinics in Surgery

Case Report
Published: 11 Nov, 2021

Bilateral Achilles Tendon Traumatic Rupture Treated with a Minimally Invasive Surgery *via* Ultrasound Guidance: A Case Report

Simone Moroni[1], Fabio Zanchini[2]*, Fabrizio Sergio[3] and Ottorino Catani[4]

[1]*Division of Podiatry, Vitruvius Institute of Biomechanics & Health, University of Vic, Spain*

[2]*Department of Orthopedics and Traumatology, Luigi Vanvitelli University, Italy*

[3]*Division of Foot Surgery, Clinic Minerva, Caserta Italy*

[4]*Department of Orthopedics and Traumatology, Maria Rosaria Clinic, Italy*

Abstract

A Rupture of the Achilles Tendon (AT) represents up to 30% of total tendons ruptures of the human body. Nevertheless it has been estimated that only 1% of these ruptures are bilateral. The authors have presented a bilateral traumatic calcaneal tendon rupture, repaired using a modified, ultrasound guided, tenolig® tenorrhaphy, on a 65-year-old patient, who has been run over by a car. High resolution Ultrasound examination documented a bilateral symmetric mid-portion subtotal AT rupture without proximal stump migration, with 20 mm of longitudinal diastasis. Eight weeks after surgery, bilateral pain free active heel rise has been restored, thus weight bearing without crutches has been allowed. This case report has shown the effectiveness with such exceptional case of a bilateral AT traumatic ruptures. Treated through a USG tenorrhaphy with tenolig®, being able to avoid the use of a more invasive procedure, leading to a relatively short time recovery and lowering complications rates.

Keywords: Achilles tendon; Ultrasound; Tenolig; Minimally invasive surgery; Achilles tendon rupture

OPEN ACCESS

Correspondence:
Fabio Zanchini, Department of Orthopedics and Traumatology, Luigi Vanvitelli University, 80100, Naples, Italy,
E-mail: fabio.zanchini@unicampania.it

Received Date: *27 Sep 2021*
Accepted Date: *08 Nov 2021*
Published Date: *11 Nov 2021*

Citation:
Moroni S, Zanchini F, Sergio F, Catani O. Bilateral Achilles Tendon Traumatic Rupture Treated with a Minimally Invasive Surgery via Ultrasound Guidance: A Case Report. Clin Surg. 2021; 6: 3354.

Copyright *© 2021 Fabio Zanchini. This is an open access article distributed under the Creative Commons Attribution License, which permits unrestricted use, distribution, and reproduction in any medium, provided the original work is properly cited.*

Introduction

A Rupture of the Achilles Tendon (AT) represents up to 30% of total tendons ruptures of the human body [1]. Nevertheless it has been estimated that only 1% of these are bilateral [2].

Diagnostic Ultrasound (US) has been found to have good reliability in confirming AT ruptures [3,4]. Consensus for the ideal surgical treatment has not yet been established, due the fact that, both open and Minimally Invasive Surgery (MIS) procedures seems to lead to complications [5-7].

Adherences due to large incisions, wounds related issues and scar fibrotizations have been reported in open repair procedures as the most prevalent complications [6,8].

Meanwhile for blinded MIS procedures, sural nerve lesions or entrapments and higher re-ruptures recurrences with respect to open techniques have been reported in literature [7].

The authors presented a bilateral traumatic calcaneal tendon rupture, repaired using a modified, ultrasound guided tenolig® tenorrhaphy, (FH Orthopedics, Heimsbrunn, France) [9], a promising surgical technique, which has shown to reduce the overall rate of complications with respect to the open and MIS procedures, improving at the same time functional outcomes and reducing recovery time [10]. Therefore, it has been hypothesized that for such exceptional case of a bilateral AT traumatic ruptures, in selected patients, such as the one which has to be presented, this technique would have been the best option.

Case Presentation

A 65-years-old patient, suffering chronic cardiovascular diseases, under antihypertensive and antiplatelet therapy without statins nor a history of fluoroquinolones antibiotics. At physical examination the hypothesis of a bilateral rupture at the AT has been made, after having been run over by a car 12 h earlier.

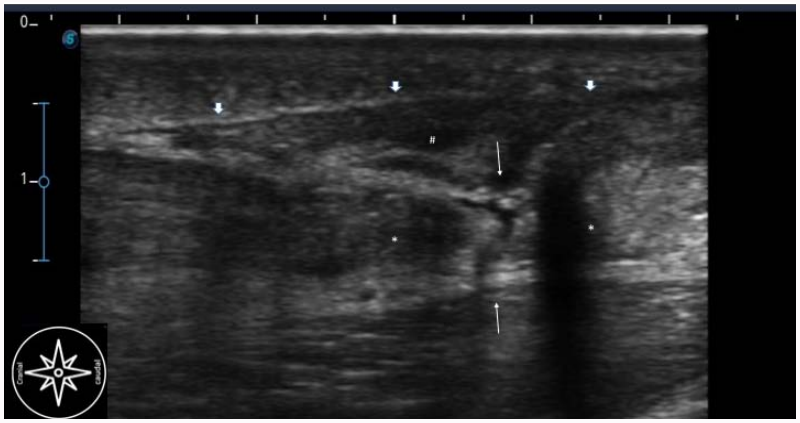

Figure 1: Diagnostic ultrasound in the long axis, lateral aspect of the left Achilles tendon (before surgery). With left ankle in slightly plantar-flexed position. Short white arrows fascia cruris/paratenon, slim white arrows Achilles tendon rupture site, white * proximal and distal Achilles tendon stumps, # hemorragic tissue.



Figure 2: Diagnostic ultrasound in the long axis, medial aspect of the left Achilles tendon (before surgery). With left ankle in slightly plantar-flexed position. Short black arrowheads showing residual AT fibers at its most dorso-medial aspect, white asterisk * proximal and distal Achilles tendon stumps, # mixed hemorragic/fat interposition tissues.

Bilateral swollen retrocalcaneal region, inability to actively plantar flexion of the ankle has been found and a slightly positive Thompson test (+ left, + right) has been shown.

High resolution US examination documented, bilateral symmetric mid portion AT rupture, mimicking a full thickness tear, presenting bilaterally a slight proximal stump migration (20 mm of longitudinal diastasis) of its ventral portion (Figure 1). However, few residual AT fibers at its most dorso-medial aspect showed continuity at both sides (Figure 2). Both tendon's echo texture revealed signs of degenerative changes, attributable to an inveterate tendinosis of the mid-portion with high power Doppler flow signal and little heterogenic soft calcifications at left AT.

Therefore the US diagnosis was consistent with bilateral subtotal AT rupture.

Once the proposed treatment has been accepted by the patient, an Ultrasound Guided (USG) tenolig® tenorrhaphy has been scheduled and performed as described by Lacoste at al. [10], under local anesthesia and without needing of a tourniquet due to the USG nature of the procedure. The surgical procedure has been performed with the patient in prone position, sural nerve course and AT proximal and distal stumps have been drawn on the skin under USG using a Sonoscape® S9 ultrasound machine with an high frequency (12 MHz to 16 MHz) linear probe. Every resulting surgical step has been performed USG.



Figure 3: Clinical iconography showing bilateral tenolig® system at 2 weeks after surgery.

Two articulated below the knee casts were then applied in a slightly plantar flexed ankle fashion (15°) and due to the bilateralism of the procedure no weight bearing has been allowed and a wheelchair has then been prescribed during 25 days after surgery.

After 25 days since surgery casts were then moved to 90° and partial weight-bearing has been allowed with crutches (Figure 3).



Figure 4: Clinical iconography showing bilateral posterior crural region after tenolig® system has been removed (4 weeks post-op).

After 40 days the surgical procedure has taken place, tenolig® system and the casts have been removed, physical therapy program has been started with active and passive exercises and cautious walking with crutches has been allowed wearing heel lifts which started with 2 cm in height, reducing it (0.5 cm) weekly.

After 8 weeks surgery, bilateral pain free active weight bearing heel rise has been restored, therefore weight bearing without crutches has been allowed.

Serial ultrasound examinations, included dynamic ones, has marked every and each post op step, staging over time the healing process of the lesions (Figure 4). Mild physical, non-high impact activities have been allowed from 4 months since surgery.

Discussion

The acute bilateral rupture of the calcaneal tendon has found to be an exceptional condition in podiatric pathology according to the literature [11-14].

Currently there have not been found a standardized therapeutic protocol, capable of guiding foot and ankle specialists in choosing the best treatment options in acute AT rupture either unilateral or bilateral [15].

The main factor that had led the authors in choosing USG procedure for this case was due to the fact that they would found theoretically lower rate of complications with respect to open and blinded MIS procedures, while restoring the patient's autonomy in the shortest possible time [10].

Conservative treatment has not been choose as an option for this case due to the overall rate of rerupture prevalence, which has been estimated around 10% [16].

Despite what previously thought, both open and blinded MIS AT tenorraphies surgeries reported similar rates of re-ruptures, 2.7% and 3.1% respectively, showing a non statistical difference in a recent meta-analysis regarding recurrences [8]. Recently, due to US technical and scientific research progresses in foot and ankle sono-anatomy, there have been described and validated many safe USG procedures [8,17-22]. For the above mentioned reasons has been chosen an USG tenolig® technique which has been found to have only 1.3% of re-ruptures prevalence [10]. Moreover, sural nerve iatrogenic damages and wound related procedure's complications such as dehiscences and superficial or deep infections has been shown to be far lower in USG procedures with respect to either open or blinded MIS procedures [10].

US examination has shown high reliability in diagnosing AT ruptures, however for partial ruptures accuracy, the literature is still conflicting [3,4]. The limitations typically attributed to USG related procedures in this case can be denied since the learning curve has found to be relatively short for this AT procedure and sural nerve can be easily found just adjacent to the small saphenous vein in order to avoid its damage [10].

The only inconvenient attributable to this USG tenolig® AT reparative surgery that authors could advise, further reported in literature as a frequent "limitation"[10], was given by the discomfort for the patient in relation to the distal "buttons" that are laying in direct contact with the skin, leading to its irritations and/or decubitus lesions, that in any case would heal without complications [10]. For the authors, this inconvenience could be avoided easily using soft sterile dressings bandages in between those two structures. This case report has shown the effectiveness and feasibility with such exceptional case of a bilateral AT traumatic rupture which, to our knowledge, has never been treated through a USG tenorrhaphy with tenolig®.

In conclusion, this procedure has being able to avoid the use of a more invasive technique, leading to a relatively short time recovery and lowering complications rates in such patients with comorbidities.

References

1. Clanton TO, Haytmanek CT, Williams BT, Civitarese DM, Turnbull TL, Massey MB, et al. A biomechanical comparison of an open repair and 3 minimally invasive percutaneous Achilles tendon repair techniques during a simulated, progressive rehabilitation protocol. Am J Sports Med. 2015;43(8):1957-64.
2. Orava S, Hurme M, Leppilahti J. Bilateral Achilles tendon rupture: A report on two cases. Scand J Med Sci Sports. 2008;6(5):309-12.
3. Margetić P, Miklić D, Rakić-Eršek V, Doko Z, Lubina ZI, Brkljačić B. Comparison of ultrasonographic and intraoperative findings in Achilles tendon rupture. Coll Antropol. 2007;31(1):279-84.
4. Alfredson H, Masci L, Öhberg L. Partial mid-portion Achilles tendon ruptures: New sonographic findings helpful for diagnosis. Br J Sports Med. 2011;45(5):429-32.
5. Metz R, Verleisdonk EJMM, Van Der Heijden GJMG, Clevers GJ, Hammacher ER, Verhofstad MHJ, et al. Acute Achilles tendon rupture: Minimally invasive surgery versus nonoperative treatment with immediate full weight bearing - A randomized controlled trial. Am J Sports Med. 2008;36(9):1688-94.
6. Khan RJK, Fick D, Keogh A, Crawford J, Brammar T, Parker M. Treatment of acute Achilles tendon ruptures: A meta-analysis of randomized, controlled trials. J Bone Joint Surg Am. 2005;87(10):2202-10.
7. Wilkins R, Bisson LJ. Operative versus nonoperative management of acute Achilles tendon ruptures: A quantitative systematic review of randomized controlled trials. Am J Sports Med. 2012;40(9):2154-60.
8. Yang B, Liu Y, Kan S. Peer review report 1 on "Outcomes and complications of percutaneous versus open repair of acute Achilles tendon rupture: A meta-analysis." Int J Surg. 2017;37:256.
9. Delponte P, Potier L, De Poulpiquet PB. Treatment of subcutaneous ruptures of the Achilles tendon by percutaneous tenorraphy. Rev Chir Orthop Reparatrice Appar Mot. 1992;78(6):404-7.

10. Lacoste S, Féron JM, Cherrier B. Percutaneous Tenolig® repair under intra-operative ultrasonography guidance in acute Achilles tendon rupture. Orthop Traumatol Surg Res. 2014;100(8):925-30.

11. Habusta SF. Bilateral simultaneous rupture of the Achilles tendon: A rare traumatic injury. Clin Orthop Relat Res. 1995;320:231-4.

12. Andrew E. Bilateral simultaneous Achilles tendon ruptures.

13. Hashim Z, Dahabreh Z, Bin Jemain MT, Williams HR. Bilateral simultaneous Achilles tendon rupture in the absence of risk factors. Foot Ankle Spec. 2011;4(3):175-8.

14. Ellanti P, Davarinos N, Burke TE, D'Souza LG. Long-term functional outcome of bilateral spontaneous and simultaneous Achilles tendon ruptures. Foot Ankle Spec. 2012;5(5):318-20.

15. Ebinesan AD, Sarai BS, Walley GD, Maffulli N. Conservative, open or percutaneous repair for acute rupture of the Achilles tendon. Disabil Rehabil. 2008;30(20-22):1721-5.

16. Deng S, Sun Z, Zhang C, Chen G, Li J. Surgical treatment versus conservative management for acute Achilles tendon rupture: A systematic review and meta-analysis of randomized controlled trials. J Foot Ankle Surg. 2017;56(6):1236-43.

17. Vohra PK, Japour CJ. Ultrasound-guided plantar fascia release technique: A retrospective study of 46 feet. J Am Podiatr Med Assoc. 2009;99(3):183-90.

18. Villanueva M, Iborra A, Rodriguez G, Sanz-Ruiz P. Ultrasound-guided gastrocnemius recession: A new ultra-minimally invasive surgical technique. BMC Musculoskelet Disord. 2016;17:409.

19. Fernandez-Gibello A, Moroni S, Camunas G, Montes R, Zwierzina M, Tasch C, et al. Ultrasound-guided decompression surgery of the tarsal tunnel: A novel technique for the proximal tarsal tunnel syndrome-part II. Surg Radiol Anat. 2019;41:43-51.

20. Moroni S, Gibello AF, Zwierzina M, Nieves GC, Montes R, Sanudo J, et al. Ultrasound-guided decompression surgery of the distal tarsal tunnel: A novel technique for the distal tarsal tunnel syndrome-part III. Surg Radiol Anat. 2019;41(3):313-21.

21. Moroni S, Zwierzina M, Starke V, Moriggl B, Montesi F, Konschake M. Clinical-anatomic mapping of the tarsal tunnel with regard to Baxter's neuropathy in recalcitrant heel pain syndrome: Part I. Surg Radiol Anat. 2019;41(1):29-41.

22. Sergio F, Catani O, Fusini F, Langella F, Cautiero G, Ponzo I, et al. Treating Haglund's deformity with percutaneous Achilles tendon decompression: A case series. Muscles Ligaments Tendons J. 2018;8(4):488-94.